

Letter to the Editor

COL1A1 is a fusionpartner of USP6 in myositis ossificans – FISH analysis of six cases

Dear Editor,

USP6 rearrangement is a consistent genetic driver event in nodular fasciitis, aneurysmal bone cyst and giant cell lesion of small bones. These lesions belong to the group of self-limiting diseases of soft tissue and bone showing histologically a cell culture-like myofibroblastic proliferation merging variably with osteoid and bone and osteoclastic giant cells [1, 2].

Recently, we identified *USP6* rearrangements in myositis ossificans expanding the spectrum of the mentioned clonal transient neoplasms [3].

Sukov et al. investigated twelve cases of myositis ossificans and found in two instances *USP6* rearrangements. They referred them to as aneurysmal bone cyst of soft tissue and demonstrated *USP6-COL1A1* in one case [4]. Another case of soft tissue aneurysmal bone cyst showed cytogenetically a translocation $t(17;17)(p13;q21)$ corresponding to

COL1A1 and *USP6* loci [5].

This prompted us to analyze *COL1A1* FISH in our reported *USP6* rearranged myositis ossificans cases by Bekers et al. [3].

USP6 signals were considered positive if at least 20% of the 50 counted cells showed split signals.

Four out of six cases harbored *COL1A1* rearrangement (Fig. 1) indicating *COL1A1-USP6* fusions in a subset of myositis ossificans.

It seems that the *COL1A1* promoter binds to the *USP6* coding sequence leading to transcriptional upregulation and oncogenic activation of *USP6*. This mechanism is similar to the remaining *USP6*-related fusion genes in all other lesions mentioned above [1]. *COL1A1-USP6* has also been identified in aneurysmal bone cyst underpinning a relationship. It is therefore not surprising that overlapping features of myositis ossificans and aneurysmal bone cyst of soft tissue are discussed [6].

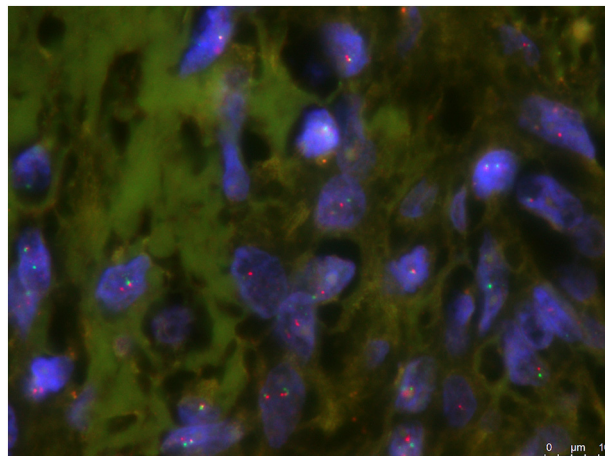


Fig. 1. *COL1A1* FISH shows break apart signals indicating rearrangement.

References

- [1] Oliveira AM, Chou MM. USP6-induced neoplasms: the biologic spectrum of aneurysmal bone cyst and nodular fasciitis. *Hum Pathol* 2014;45:1–11.
- [2] Agaram NP, LeLoarer FV, Zhang L, Hwang S, Athanasian EA, Hameed M, Antonescu CR. USP6 gene rearrangements occur preferentially in giant cell reparative granulomas of the hands and feet but not in gnathic location. *Hum Pathol* 2014;45:1147–52.
- [3] Bekers EM, Eijkelenboom A, Grünberg K, Roverts R, de Rooy JW, van der Geest IC, van Gorp JM, Creyten D, Flucke U. Myositis ossificans – another condition with USP6 rearrangement, providing evidence of a relationship with nodular fasciitis and aneurysmal bone cyst. *Ann Diagn Pathol* 2018;34:56–9.
- [4] Sukov WR, Franco MF, Erickson-Johnson M, Chou MM, Unni KK, Wenger DE, Wang X, Oliveira AM. Frequency of USP6 rearrangements in myositis ossificans, brown tumor, and cherubism: molecular cytogenetic evidence that a subset of “myositis ossificans-like lesions” are the early phases in the formation of soft-tissue aneurysmal bone cyst. *Skeletal Radiol* 2008;37:321–7.
- [5] Jacquot C, Szymanska J, Nemana LJ, Steinbach L, Horvai A. Soft-tissue aneurysmal bone cyst with translocation t(17;17)(p13;q21) corresponding to COL1A1 and USP6 loci. *Skeletal Radiol* 2015;44:1695–9.
- [6] Nielsen GP, Fletcher CD, Smith MA, Rybak L, Rosenberg AE. Soft tissue aneurysmal bone cyst: a clinicopathological study of five cases. *Am J Surg Pathol* 2002;26:64–9.

Uta Flucke^{a,*}, Elise M. Bekers^{a,b}, David Creyten^c, Joost M. van Gorp^d

^a Department of Pathology, Radboud University Medical Center, Nijmegen, the Netherlands

^b Department of Pathologie (Pathologie-DNA), Jeroen Bosch Hospital, Den Bosch, the Netherlands

^c Department of Pathology, Ghent University Hospital, Ghent, Belgium

^d Department of Pathology (Pathologie-DNA), Diaconessenhuis Utrecht, Utrecht, the Netherlands

E-mail address: uta.flucke@radboudumc.nl

* Corresponding author at: Radboud University Medical Center, Department of Pathology, P.O. Box 9101, 6500 HB Nijmegen, the Netherlands.